




AENSI Journals

## Advances in Environmental Biology

ISSN-1995-0756 EISSN-1998-1066

Journal home page: <http://www.aensiweb.com/AEB/>

## Thyroid Disruption and Infertility after Chronic Exposure to Mancozeb

Elkhansa Yahia, Mohamed Amine Aiche, Amel Chouabia, Mohamed Salah Boulakoud

Laboratory of Animal Ecophysiology, Department of Biology, Faculty of Sciences, Badji Mokhtar University, Box 12 Annaba 23000, Algeria.

### ARTICLE INFO

#### Article history:

Received 12 December 2014

Received in revised form 26 January 2015

Accepted 27 February 2015

Available online 19 April 2015

#### Keywords:

Spermatozoa, Thyroid,  
Rats, Toxicity, Mancozeb  
Testes.

### ABSTRACT

This work aims to highlight the toxic effects of mancozeb; polymeric complex of manganese and zinc ethylene bis-dithiocarbamate, on the fertility and thyroid functions. Male Wistar rats were treated orally with different doses of mancozeb: 250, 500 and 1000 mg/kg body weight/ day for 8 weeks. The obtained results showed a highly significant increase ( $p \leq 0.01$ ) on thyroid absolute weight in the groups treated with 500 and 1000 mg/kg body weight/day respectively. However, testes absolute weight witnessed a significant decrease ( $p \leq 0.05$ ) in group treated with 500 mg/kg, this decrease becomes very highly significant in the group treated with 1000 mg/kg/day. The biochemical test revealed a significant increase of cholesterol and triglycerides rates in the group treated with the highest dose. A highly significant increase of blood glucose is also observed in the groups treated with 500 and 1000 mg/kg/day. Hormone assays have shown a very highly significant decrease of thyroxine in all the groups treated with different doses, while triiodothyronine concentration witnessed a very highly significant decrease only in the group treated with 1000 mg/kg/day. Finally, the studying of biological characters of the spermatozoa showed a highly significant and very highly significant decrease in the concentration of spermatozoa and their mobility in rats treated with 500 and 1000 mg/kg/day respectively. In conclusion, it seems that long term exposure to mancozeb is associated to hypothyroidism by decreasing FT4 and FT3 and has adverse effects on testes function leading to physiological impairment.

© 2015 AENSI Publisher All rights reserved.

**To Cite This Article:** Elkhansa Yahia, Mohamed Amine Aiche, Amel Chouabia, Mohamed Salah Boulakoud, Thyroid Disruption and Infertility after Chronic Exposure to Mancozeb. *Adv. Environ. Biol.*, 9(8), 96-102, 2015

## INTRODUCTION

Pesticides are the most important chemicals used mainly in agriculture to control pest animals (insects, rodents), fungi and weeds. A World Bank (2008) report estimates that 355,000 people worldwide die each year from unintentional pesticide poisoning. Many data have shown the relationship between chronic pesticide exposure and health condition impairment, including carcinogenesis, neurotoxicity, reproductive and growth disturbance [1]. In agriculture, fungicides are used to protect fruits and vegetables during storage or are applied directly to ornamental plants, trees, field crops, cereals [2] but causing systemic poisoning in humans [3]. Mancozeb, a fungicide belonging to ethylene bis dithiocarbamate group, used to protect crops from a range of fungal diseases [4]. Despite its low acute toxicity, mancozeb has been shown to cause several effects on human and animal health, when repeated exposure can alter various functions [9]. Reports are available on the toxicity of mancozeb on central nervous system [6, 7] and Histopathological changes in testis of the mice treated with high doses of mancozeb revealed spermatogenesis inhibition [8], the presence of manganese and zinc in the additional formula could also cause production of free radicals [9]. Also the exposure was tested on laboratory animals by causing histopathological changes in the adrenal gland, liver and kidneys [10]. This study describes widely used fungicide; mancozeb and its effects on male rats, particularly on thyroid and reproductive functions using different doses: 1/5, 1/10 and 1/20 LD<sub>50</sub> of mancozeb for rats.

## MATERIAL AND METHODS

*Animals and experimental conditions:* This work was carried out on 32 adult male Wistar rats (aged between 06 and 08 weeks and weighing  $240 \pm 20$ g) obtained from the Pasteur Institute-Algeria. The protocol

**Corresponding Author:** Elkhansa Yahia, Faculty of Sciences, Department of Biology, Laboratory of Animal Ecophysiology, University Badji Mokhtar-Annaba BP 12, Annaba 23000, Algeria  
E-mail: khansayahia@ymail.com

was conducted as follows: Rats were divided into 4 groups of 8 individuals. G1 was held as a control group and G2, G3 and G4 were treated by 250, 500 and 1000 mg/kg/day respectively. It is noteworthy that these rats were previously acclimated for two weeks with standard laboratory conditions (temperature:  $22 \pm 2^\circ\text{C}$ , natural photoperiod 12L/12D and relative humidity: 40 - 60%) before being subjected to the treatment with an *ad libitum* access to Water and food.

**Treatment:** The used concentrations were taken from a stock solution containing mancozeb (80% soluble powder) diluted in water and administered orally in early morning with a stomach tube at the used doses: 250, 500 and 1000 mg / kg of the body weight/ day for 8 weeks.

**Biochemical assay:** At the end of the treatment, the rats were sacrificed and the arterio-venous blood has been collected in dry tubes then centrifuged to obtain serum to perform the assay parameters affected by thyroid and reproductive activity according to the Kaplan method [11,12], while the FT3 and FT4 assay was performed according to the enzyme-linked immunosorbent assay (ELISA).

**Sperm analysis:** To evaluate the adverse effects of mancozeb fungicide on rats' fertility, a study of biological characters of sperm and semen quality has been preceded according to the WHO method to determine the sperm concentration and mobility [13].

**Statistical analysis :** Statistical analysis of data was expressed as mean values  $\pm$  SD, analyzed by Student's *t* test (MINITAB Version 16).

### Results:

**Organs weight:** The obtained results (Table 1) show a very highly significant increase in thyroid absolute weight of groups treated with 500 and 1000 mg/kg/day, group treated with 250mg/kg showed significant increase compared to the control one, however left testis weight showed highly significant decrease only in groups treated with 500 and 1000mg/kg respectively.

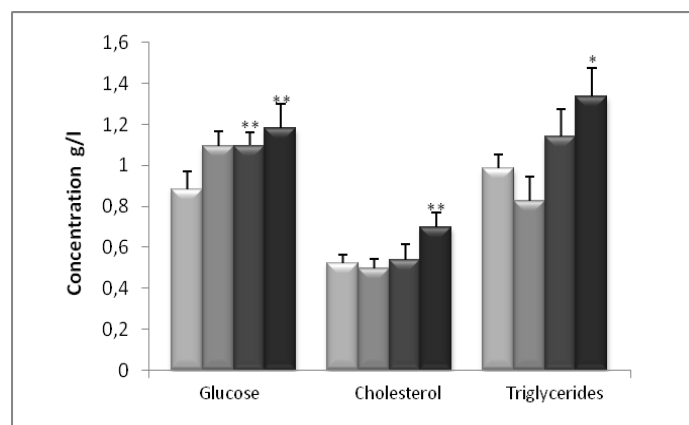
**Table 1:** Weight of testes and thyroid in control and treated rats with 250, 500 and 1000 mg/body weight/ day during 8 weeks.

Weight (g)	G1: Control	G2: 250 mg/kg	G3: 500 mg/kg	G4: 1000 mg/kg
Left testis	1.72 $\pm$ 0.067	1.68 $\pm$ 0.031	1.58 $\pm$ 0.060*	1.52 $\pm$ 0.080**
Thyroid	0.018 $\pm$ 0.0011	0.022 $\pm$ 0.0019*	0.027 $\pm$ 0.0026**	0.029 $\pm$ 0.0029***

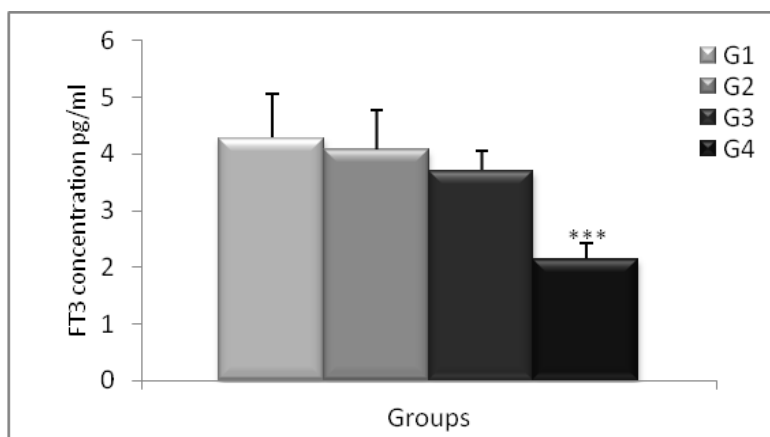
**Biochemical analysis:** The obtained results (Graph 1) reveal a highly significant increase in glucose serum concentration between the control and treated groups with 500 and 1000mg/kg. However, a variation is recorded in cholesterol and triglycerides serum that increases significantly only in the group treated with 1000 mg/kg/day.

**Hormone analysis:** Analysis of FT3 (Graph 2), and FT4 (Graph 3) levels reveals a very highly significant decrease of the free thyroxine concentration (T4) in all treated groups compared to the control one, while the free T3 concentration witnessed a very highly significant decrease in the group treated with the highest dose only.

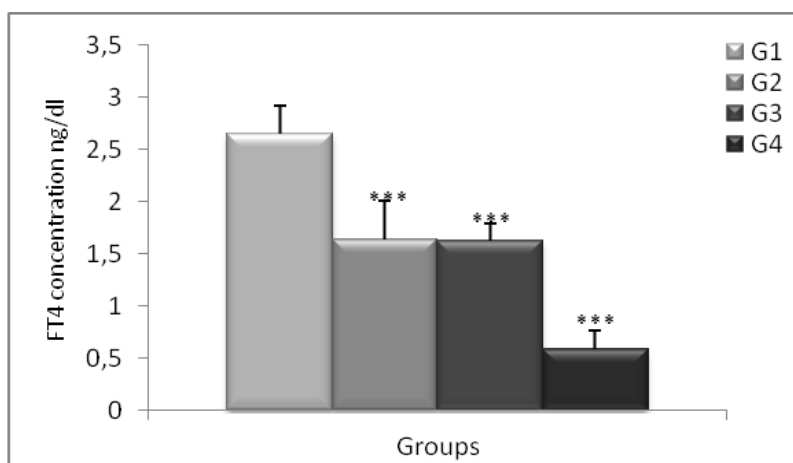
**Semen study:** The study of the biological characters of the spermatozoa revealed a significant decrease in the concentration of sperm count, estimated at 11, 37 and 56% for those treated with mancozeb at the concentrations: 250, 500 and 1000 mg/kg /day respectively (Graph 4). Sperm mobility was also affected by the treatment; a decrease of 37, 57 and 60% has been witnessed in groups all treated groups (Graph 5).



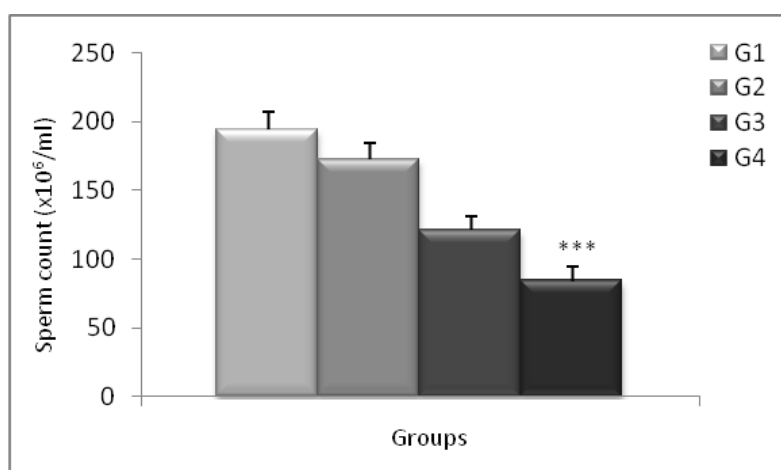
**Graph. 1:** Changes in serum glucose, cholesterol and triglycerides of control and treated rats with 250, 500 and 1000 mg/body weight/ day during 8 weeks. (G1 as control, G2, G3 and G4 as treated group). Significant differences \*  $P \leq 0.05$ . \*\*  $P \leq 0.01$



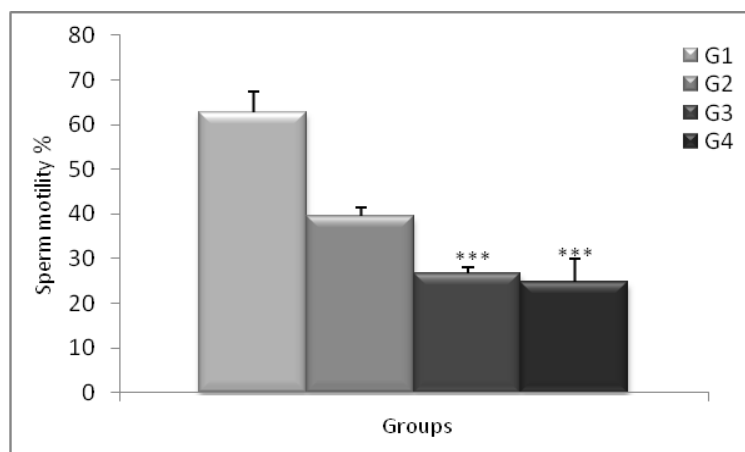
**Graph. 2:** Changes in FT3 serum concentration of control and treated rats with 250, 500 and 1000 mg/body weight/ day during 8 weeks. (G1 as control, G2, G3 and G4 as treated group). Significant difference \*\*\*  $P \leq 0.001$



**Graph. 3:** Changes in FT4 serum concentration of control and treated rats with 250, 500 and 1000 mg/body weight/ day during 8 weeks. (G1 as control, G2, G3 and G4 as treated group). Significant difference \*\*\*  $P \leq 0.001$



**Graph. 4:** Mean changes in sperm count of control and treated rats with 250, 500 and 1000 mg/body weight/ day compared to control during 8 weeks. (G1 as control, G2, G3 and G4 as treated group). Significant difference \*\*\*  $P \leq 0.001$ .



**Graph. 5:** Altered sperm motility (%) of treated rats with 250, 500 and 1000 mg/body weight/ day compared to control during 8 weeks. (G1 as control, G2, G3 and G4 as treated group). Significant difference \*\*\* $P < 0.001$ .

#### Discussion:

The environmental exposures, specifically to pesticides, have potential risk factors for food consumers, production workers, formulators, farmers and other [14]. It has been known that using pesticides caused poisoning and potential toxicity to biological system [15,16]. Several research have shown that the carbamate can alter biochemical parameters in experimental animals [17,18,19]. The obtained results are summarized as follow: administration of mancozeb at different doses does not induce violent toxicity leading to mortality, however it induces increase in cholesterol and triglyceride levels in most treated groups. This increase in serum cholesterol can be attributed to the effect of pesticides on the permeability of the liver cell membrane [20,21], our result are similar to those obtained by Djeflal *et al.*, 2012 who founded an increase in cholesterol and triglyceride levels of the rats after exposing to methomyl [22]. In addition, the observed rise of serum cholesterol concentration, which is associated with the increase in triglycerides, may indicate a possible membrane lipid peroxidation [23] or a result of a dysfunction in the steroidogenesis process in leydig cells [24]. Our results show also an increase in glucose serum concentration in rats treated with different doses. This hyperglycemia is similar to the observations of Mallem *et al.*, 2006 who observed an increase in glucose serum level after exposing rabbits to maneb [25], also other results showed some levels higher than the glucose standard level in rats exposure to carbamate insecticides as thiodicarbe [26].

Thyroid hormones are known by their role in the basal metabolism and energy homeostasis of the body [27,28] and their deficiency may impair the good thyroid functioning. According to the above mentioned results, a decrease in the concentration level of T3 and T4 has been witnessed in all the groups treated with mancozeb; this decrease is explained by the direct action of mancozeb on thyroid through inhibition of the hormones production [29]. Other studies have also shown that dithiocarbamates affect the activity of the thyroid by decreasing the TSH secretion. This causes a decrease of the circulating T4 and an induction of hypothyroidism [30] since the TSH secretion is dependent on the homeostasis of the hypothalamic-pituitary-thyroid axis [31]. It is noteworthy that many research works on this topic led to the conclusion that mancozeb may have a direct effect on the thyroid by inhibiting the synthesis of thyroxine or accelerating its deiodination. [8].

Studies on the pesticides impact have shown that constant exposure to these substances could lead to disruptions of the thyroid [32] among which hypothyroidism is the most common abnormality after chronic exposure to benomyl, maneb and mancozeb [33]. Several studies have reported that the thyroid disturbances act through various mechanisms, such as inhibition of the iodine thyroid absorption, the interference in thyroid hormone receptor [34, 35] or by the inhibition of the thyroperoxydase enzyme involved in the thyroid hormones biosynthesis [36]. The results obtained on the thyroid gland revealed a significant increase in its weight in rats treated with 500 and 1000mg/kg. These results are similar to those of Mahadevaswami *et al.*, 2000 [37] and Baligar and Kaliwal, 2001 [38].

Sperm quality evaluation revealed an alteration of reproductive parameters mainly the most important biological characters of the spermatozoa: concentration and mobility. This alteration can be explained by mancozeb effect on testes, since gonads are target organs for many pesticides [39]. The observation made on the testes weight revealed their significant decrease in most threated groups with mancozeb in a dose-dependent manner. This result may be caused by testicular atrophy accompanied with a damage of the germinal epithelium. Other studies on ethylenebis-dithiocarbamate metabolites suggested that carbon disulfide; the major metabolite of mancozeb, causes testicular and epididymal degeneration, and thus affects spermatogenesis [40]. Research works conducted on animals exposed to a variety of carbamate insecticides revealed a degeneration of the

seminiferous tubules and consequently an alteration of the histological and morphological constitution of testes [41]. An exposure of adult rats to 300 mg/kg/day for 60 days mancozeb showed a decrease in testicular weight possibly due to the loss of germ cells [42]. These findings are in accordance with previous studies on rats [43] and Swiss mice [44]. Sperm analysis revealed a significant decrease in sperm concentration and mobility in all groups treated with mancozeb compared to the control one. This alteration is possibly due to a dysfunction of Sertoli cells, responsible for the maintenance of spermatogenesis. Pant *et al.*, 1999 observed a decrease in sperm motility and their number along with an increase of abnormal spermatozoa in rats exposed to carbofuran [45]. These results are in accordance with those of Nakai *et al.*, 2002 who suggested that exposure to maneb causes a structural imbalance of the tubulin which consequently slows spermatogenesis at the spermatid stage [46]. The decrease of sperm motility may be caused by morphological defects in the intermediate piece and the flagellum which ensure spermatozoa's movement and speed [47].

A similar study on male rats frequently exposed to carbendazim revealed a decrease in sperm motility because of an alteration in the flagellum; composed of protein that can be a target for many endocrine disruptors [48]. Some other researches applied on rats subjected to methyl thiophanate showed an impairment of the spermatogenesis in Sertoli cells [49] responsible for sperm nutrition [50].

Recent researches have associated male or female infertility to thyroid dysfunction. Our results revealed lower rates of thyroxine and T3 causing hypothyroidism. This latter is involved in the reduction of the rate of sex hormone binding globulin (SHBG) as well as the decrease in testosterone [51]. A study concluded that hypothyroidism affects sperm quality through the decrease of the volume and sperm motility [52].

#### *Conclusion:*

The results of this study show the toxic effects of mancozeb; a pesticide widely used in agriculture on the biological characteristics of sperm as well as the parameters involved in thyroid function in Wistar rats. Toxicity has been evaluated by the disturbance of biochemical metabolism and the thyroid hormone profile in all treated groups, cause severe hypothyroidism accompanied by impairing fertility factors. The health of people repeatedly exposed can also be threatened in medium term.

#### ACKNOWLEDGEMENT

The study present the national research project (PNR) funded by The Ministry of Higher Education and scientific Research. The authors are grateful to laboratory of Animal Ecophysiology and Pasteur Institute Algiers for helpful assistance

#### REFERENCES

- [1] Hernández, A.F., M.A. Gómez, V. Pérez., J.V. García-Lario, G. Pena, F. Gil., O. López, L. Rodrigo, G. Pino and A. Pla, 2006. Influence of exposure to pesticides on serum components and enzyme activities of cytotoxicity among intensive agriculture farmers. *Environmental Research*, 102: 70–76.
- [2] Gupta, P.K. and M. Aggarwal, 2007. Toxicity of fungicides. In: *Veterinary Toxicology*, Gupta, R. C. (Ed.), 1st ed., 587-601, Elsevier, 978-0-12-370467-2, New York.
- [3] Mortazavi, F. and A. Jafari-Javid, 2009. Acute renal failure due to copper sulphate poisoning; a case report. *Iranian Journal of Pediatrics*, 19(1): 75-78, 1018-4406.
- [4] Paro, R., G.M. Tiboni, R. Buccione, G. Rossi, V. Cellini and R. Canipari, 2012. The fungicide mancozeb induces toxic effects on mammalian granulosa cells. *Toxicology and Applied Pharmacology*, 260: 155–161.
- [5] Axelstad, J., J. Boberg, C. Nellemann, M. Kiersgaard, P.R. Jacobsen, S. Christiansen, K.S. Hougaard and U. Hass, 2011. Exposure to the widely used fungicide mancozeb causes thyroid hormone disruption in rat dams but no behavioral effects in the offspring. *Toxicol. Sci*, 120: 439–446
- [6] Nordby, K.C., A. Andersen, L.M. Irgens and P. Kristensen, 2005. Indicators of mancozeb exposure in relation to thyroid cancer and neural tube defects in farmers' families. *Scand J Work Environ Health*, 31: 89–96.
- [7] Tsang, M.M. and L.D. Trombetta, 2007. The protective role of chelators and antioxidants on mancozeb-induced toxicity in rat hippocampal astrocytes. *Toxicol Ind Health*, 8: 459-470.
- [8] Ksheerasagar, L.R. and B.B. Kaliwal, 2010. Effect Of Mancozeb On Thyroid, Testis, Accessory Reproductive Organs And Biochemical Constituents In Albino Mice. *Recent Research in Science and Technology*, 2(8): 07-17.
- [9] Negga, R., J.A. Stuart, M.L. Machen, J. Salva., A.J. Lizek, S.J. Richardson, A.S. Osborne, O. Mirallas, K.A. McVey and V.A. Fitsanakis, 2012. Exposure to glyphosate and/or Mn/Zn-ethylene-bis dithiocarbamate-containing pesticides leads to degeneration of g-aminobutyric acid and dopamine neurons in *Caenorhabditis elegans*. *Neurotox Res*, 21: 281–290.

- [10] Sakr, S.A., 2007. Ameliorative effect of ginger (*Zingiber officinale*) on mancozeb fungicide induced liver injury in Albino rats. *Australian J. Bas. Appl*, 1: 650–656.
- [11] Kaplan, L.A., 1984. Glucose. In *Clinical chemistry: theory, analysis, and correlation*. Edited by Kaplan L.A. and Pesce A.J. Mosby, St. Louis. Toronto. Princeton, pp: 1032–1036.
- [12] Kaplan, L.A., F.F. Rubaltelli, C. Hammerman, M.T. Vilei., C. Leiter and A. Abramov. Triglycerides, 1984. *Clin. Chem. The C.V. Mosby Co. St Louis. Toronto. Princeton*, pp : 1194-1206.
- [13] Organisation Mondiale de la Santé (O.M.S), 1993. Analyse du sperme humain et de l'interaction des spermatozoïdes avec le mucus cervical. Ed.INSERM, pp: 55-56.
- [14] Rao, M.V., R.S. Sundar and S.L. Chawla, 2005. Reproductive toxicity of a fungicide combination (metalaxyl + mancozeb) in adult male rats. *Journal of Cell and Tissue Research*, 5(1): 299-302.
- [15] Kayacan, S.M., S. Vatansever, V. Akkaya, O. Erk, T. Tukek, I. Kılıcaslan, A. Yildiz and K. Guler, 2007. A case of copper sulfate intoxication that is presented with prolonged hemolysis and acute renal failure. *Journal of Istanbul Faculty of Medicine*, 70: 47-50, 1305-6441.
- [16] Calvert, G.M., J. Karnik, L. Mehler, J. Beckman, B. Morrissey, J. Sievert, R. Barret, M. Lackovic, L. Mabee, A. Schwartz, Y. Mitchell and S. Moraga-McHaley, 2008. Acute pesticide poisoning among agricultural workers in the United States, 1998– 2005. *American Journal of Industrial Medicine*, 51: 883–898, 0271-3586.
- [17] Garg, D.P., A.K. Bansal, A. Malhotra, R. Kiran and D.K. Dhawan, 2009. Methomyl induced hematological and biochemical alterations protection by vitamin E. *Pesticide Biochemistry and Physiology*, 93(3): 127–132.
- [18] Garg, D.P., P. Bhalla, R. Kiran, A.K. Bansal and D.K. Dhawan, 2009a, Vitamin E-mediated protection in methomyl induced alterations in rat liver. *Toxicological and Environmental Chemistry*, 91(4): 685–698.
- [19] aramiz-Mohajeri, S. and M. Abdollahi, 2011. Toxic influence of organophosphate, carbamate, and organochlorine pesticides on cellular metabolism of lipids, proteins, and carbohydrates: a systematic review. *Human and Experimental Toxicology*, 30(9): 1119–1140.
- [20] Yousef, M.I., F.M. Demerdash., K.I. Kamei and K.S. Salhen, 2003. Changes in some hematological and biochemical indices of rabbits induced by isoflavones and cypermethrin. *Toxicology*, 189: 223–234.
- [21] Yousef, M.I., T.I. Awad and E.H. Mohamed, 2006. Deltamethrin-induced oxidative damage and biochemical alterations in rat and its attenuation by vitamin E. *Toxicology*, 227(3): 240–247.
- [22] Djeffal, A., M. Messarah, A. Boumendjel, L. Kadeche and A. El Feki, 2012. Protective effects of vitamin C and selenium supplementation on methomyl-induced tissue oxidative stress in adult rats. *Toxicology and Industrial Health*, 31(1): 31-43.
- [23] Saoudi, M., M. Messarah, A. Boumendjel, K. Jamoussi and A. El Feki, 2011. Protective effects of vitamin C against haematological and biochemical toxicity induced by deltamethrin in male Wistar rats. *Ecotoxicology and Environmental Safety*, 74: 1765–1769.
- [24] Kechrid, Z., N. Layachi, E. Derai, L. Mellahi and N. Bouzerna, 2007. Effect of mancozeb on the metabolism and enzymatic activities of transaminases and alkaline phosphatase in albino wistar rats. *African Crop Science Conference*, pp: 1709-1711.
- [25] Mallem, L., M.S. Boulakoud and M. Franck, 2006. Hypothyroidism after medium exposure to the fungicide maneb in the rabbit *cuniculus lepus*. *Commun Agric Appl Biol Sci*, pp: 91-99.
- [26] Al-Shinnawy, M.S., 2008. Assessment of the changes in some diagnostic parameters in male albino rats (*Rattus norvegicus*) toxicated with thiodicarb insecticide. *Egypt. Acad. J. Biol. Sci*, 1(2): 157-166.
- [27] Silvestri, E., L. Schiavo, A. Lombardi and F. Goglia, 2005. Thyroid hormones as molecular determinants of thermogenesis. *Acta Physiol Scand*, 184: 265–283.
- [28] Schriks, M., J.M. Roessig, A.J. Murk and J.D. Furlow, 2007. Thyroid hormone receptor iso form selectivity of thyroid hormone disrupting compounds quantified with an in vitro reporter gene assay. *Environ. Toxicol. Pharmacol*, 23(3): 302–307.
- [29] Cocco, P., 2002. On the rumors about the silent spring. Review of the scientific evidence linking occupational and environmental pesticide exposure to endocrine disruption health effects. *Cad Saúde Pública*, 18(2): 379–402.
- [30] Jeffrey, M., C. Charles., R. Thomas, J.R. Hanley, D.W. Ronald, V.R. Bernard and S.B. James, 2001. Developmental toxicity studies in rats and rabbits on 2,4-dichlorophenoxyacetic acid and its forms. *Toxicol Sci*, 60: 121-131.
- [31] Sadow, P.M., O. Chassande, K. Gauthier, J. Samarut, J. Xu., B.W. O'Malley, H. Seo, Y. Murata and R.E. Weiss, 2003. Specificity of thyroid hormone receptor subtype and steroid receptor coactivator-1 on thyroid hormone action. *Am J Physiol Endocrinol Metab*, 284(1): 36-46.
- [32] Patrick, L., 2009. Thyroid disruption: mechanisms and clinical implications in human health. *Altern Med Rev*, 14(4): 326-346.

- [33] Goldner, W.S., D.P. Sandler, F. Yu, J.A. Hoppin, F. Kamel and T.D. LeVan, 2010. Pesticide use and thyroid disease among women in the agricultural health study. *American Journal of Epidemiology*, 171(4): 455–464.
- [34] Boas, M., U. Feldt-Rasmussen, N.E. Skakkebaek and K.M. Main, 2006. Environmental chemicals and thyroid function. *European Journal Endocrinology*, 154(5): 599–611.
- [35] Zoeller, R.T., 2007. Environmental chemicals impacting the thyroid: targets and consequences. *Thyroid*, 17(9): 811–817.
- [36] Moyer, P.B., 1997. Reproductive and Endocrine Toxicology. In: Sipes IG, McQueen CA, Gandolfi AJ, ed(s). *Comprehensive Toxicology*. Elsevier Science direct.
- [37] Mahadevaswami, M.P., U.C. Jadaramkunti, M.B. Hiremath and B.B. Kaliwal, 2000. Effect of mancozeb on ovarian compensatory hypertrophy and biochemical constituents in hemicastrated albino rat. *Reprod. Toxicol*, 14(2): 127-134.
- [38] Baligar, P.N. and B.B. Kaliwal, 2001. Induction of gonadal toxicity to female rats after chronic exposure to mancozeb. *Industrial Health*, 39: 235-243.
- [39] Kojima, S., Y. Sugimura, H. Hirukawa, M. Kiyozumi, H. Shimada and T. Funakoshi, 1992. Effects of dithiocarbamates on testicular toxicity in rats caused by acute exposure to cadmium. *Toxicol Appl Pharmacol*, 116(1): 24-29.
- [40] Patel, K.G., A.K. Gautam and Y.V. Vaghasia, 1999. Carbon disulphide induced impairments in male reproductive system in rats. *Indian Journal of Physiology and Allied Sciences*, 53(1): 22-28.
- [41] Ezeasor, D.N., 1990. Light and electron microscopical observations on the Leydig cells of the scrotal and abdominal testis of naturally unilateral cryptorchid West African dwarf goats. *Journal of Anatomy*, 141: 27–40.
- [42] Ananthan, G. and B. Kumaran, 2013. Effect of Mancozeb on the Specific activities of Testicular Phosphatases and Protective role of Vitamin C in Albino rats. *Bulletin of Environment, Pharmacology and Life Sciences*, 2(7): 56-61.
- [43] Joshi, S.C., N. Gulati and A. Gajraj, 2005. Evaluation Of Toxic Impacts Of Mancozeb On Testis In Rats. *Asian J. Exp.Sci*, 19(1): 73-83.
- [44] Ksheerasagar, R.L. and B.B. Kaliwal, 2003. Temporal effects of mancozeb on testes, accessory reproductive organs and biochemical constituents in albino mice. *Environmental toxicology and pharmacology*, 15(1): 9-17.
- [45] Pant, N., A.K. Prasad, S.C. Srivastava, R. Shankar and S.P. Srivastava, 1995. Effect of oral administration of carbofuran on male reproductive system of rat. *Hum Exp Toxicol*, 14: 889–894.
- [46] Nakai, M., M.G. Miller, K. Carnes and R.A. Hess, 2002. Stage-specific effects of the fungicide carbendazim on sertoli cell microtubules in rat testis. *Tissue cell*, 34(2): 73- 80.
- [47] Djabali, N. and K. Khelili, 2009. Contribution à l'étude de l'impact d'un fongicide (Dithiocarbamate de manganèse : Manèbe) sur quelques paramètres de la fertilité masculine chez le lapin : *Oryctolagus cuniculus*. *Afrique Science*, 5(2): 321–329.
- [48] Akbarsha, M.A., B. Kadalmani, R. Girija, A. Faridha and K.S. Hamid, 2001. Spermatotoxic effect of carbendazim. *Indian Journal of Experimental Biology*, 39(9): 921–924.
- [49] Markelewicz, R.J. Jr., S.J. Hall and K. Boekelheide, 2004. 2,5-hexanedione and carbendazim coexposure synergistically disrupts rat spermatogenesis despite opposing molecular effects on microtubules. *Toxicological Sciences*, 80(1): 92–100.
- [50] Jinshou, L.I., S. Lingbin, Z. Zhenghong, C. Meng, G. Hong and W. Changgang, 2012. Exposure to paclobutrazol disrupts spermatogenesis in male *Sebastiscus marmoratus*. *Aquatic Toxicology*, 122: 120-124.
- [51] Krassas, G.E. and P. Perros, 2003. Thyroid disease and male reproductive function. *J Endocrinol Invest*, 26(4): 372-380.
- [52] Singh, R. and A. Agarwal, 2011. Thyroid hormones in male reproduction and fertility. *Open reproductive science Journal*, 3: 98-104.