




AENSI Journals

## Advances in Environmental Biology

ISSN-1995-0756 EISSN-1998-1066

Journal home page: <http://www.aensiweb.com/AEB/>

## Toxicity of Subchronic Doses of Propiconazole, Propineb and Their Mixture on Reproductive Parameters in Male Rats

<sup>1</sup>Mohamed Amine Aiche, <sup>1,2</sup>Leila Mallem, <sup>1</sup>Elkhansa Yahia, <sup>1</sup>Mohamed Salah Boulakoud

<sup>1</sup>Animal Ecophysiology Laboratory, Faculty of Sciences, Badji Mokhtar University, BP 12, 23005 Sidi Amar, Annaba, Algeria

<sup>2</sup>Faculty of Medicine, Department of dentistry, Badji Mokhtar University, El Zaafrania, B.P 205, 23000 Annaba, Algeria

### ARTICLE INFO

#### Article history:

Received 21 November 2014

Received in revised form 4 December 2014

Accepted 3 January 2015

Available online 28 January 2015

#### Keywords:

Propiconazole, Propineb, Pesticides mixtures, Rats, Fertility, Histological studies.

### ABSTRACT

The present study has been carried out to elucidate the toxic effects of two commonly used pesticides, propiconazole, propineb and their mixture on reproductive parameters in male wistar rats. Twenty eight male rats were randomly divided into four groups. Rats in groups 2, 3, and 4 received propiconazole 60 mg/Kg, Propineb 100 mg/Kg and their mixture 30 mg/kg Propiconazole + 50 mg/kg Propineb, respectively, while those of group one served as control, and that throughout the 4 weeks experimental period. Animals were observed for clinical toxicity. At the end of treatment, all groups of animals were scarified and samples of different organs were fixed in the formal 10% for histopathological study. The semen study showed a decrease in the count and mobility of spermatozoa, accompanied with a significant decrease in morphological changes of flagellum in the treated groups especially with mixture compared to control group. It was also a decrease in the weight of the testis and epididymis in the treated groups compared to the control. Histological changes were observed in the testis and epididymis in all treated groups. In conclusion this paper shows clearly that the treatment with these pesticides alone or in combination for 4 weeks can induce a decrease in the quality of the sperm with histopathological changes in the testes and epididymis.

© 2015 AENSI Publisher All rights reserved.

**To Cite This Article:** Mohamed Amine Aiche, Leila Mallem, Elkhansa Yahia, Mohamed Salah Boulakoud., Toxicity of Subchronic Doses of Propiconazole, Propineb and Their Mixture on Reproductive Parameters in Male Rats. *Adv. Environ. Biol.*, 9(3), 885-891, 2015.

## INTRODUCTION

Pesticides are ubiquitous in our environment and have a significant impact on the economy, the environment and public health. Pesticide use was crucial for agricultural development and improves human nutrition through increased availability, the lifetime of storage and reduces feed costs. Pesticides also reduce human labor requirements and concomitant of industrial accident risks. These agents actively assist in the control of food-borne and vector-borne diseases [1]. Humans are exposed to complex mixtures of toxic compounds every day in their residential and occupational environments [2,3]. In particular, agrochemicals are continuously used on a massive scale and persist as residues in food of both vegetable and animal origin, as well as in the air and water [4]. Exposure to pesticides can be done by different routes (food, drinking water, housing, work) and different routes (oral, respiratory, dermal) [5, 6, 7].

The incidence of male fertility decay has increased alarmingly since 1980s as a result of multi-factorial events including environmental pollution. The number of experimental studies on the effect of agrochemicals on the reproductive system has grown in recent years and some possible mechanisms of toxicity have been suggested. The most widely accepted effect is pesticide induced endocrine-disrupting effects [8]. Several studies have indicated a correlation between pesticide exposure and reduced male fertility [9, 10, 11, 12].

In this work we studied two of the most used pesticides not only in our country but also in different part of the world. Propineb is a fungicide with the propylene-bis-dithiocarbamate. Dithiocarbamates form lipophilic complexes with di- and trivalent metallic cations, bonding through the sulfur atoms. Propineb has a low acute toxicity with a specific goitrogenic effect in rats. It has been reported that the exposure of Propineb in repeated dose toxicity studies, in addition can have an effects on the thyroid gland and reversible effects on skeletal muscles [13, 14, 15, 16, 17]. Propiconazole is a triazole containing antifungal agent widely used in agriculture

**Corresponding Author:** Mohamed Amine AICHE, Animal Ecophysiology Laboratory, Faculty of Sciences, Badji Mokhtar University, BP 12, 23005 Sidi Amar, Annaba, Algeria.  
Tel: +213 554 56 07 22; E-mail: amine\_aiche@live.fr.

[18, 19]. It used to slow or stop the growth of fungus infecting agricultural fields [20]. Studies conducted for safety and risk assessments have tested the *in vivo* effects of these triazoles in rodents and other species, demonstrating hepatotoxicity for all Propiconazole, and even possible adverse effects in oncogenicity tests in mice [21].

Present study was aimed to evaluate the adverse effects of propiconazole and propineb in the male rat when given alone or in combination. This may contribute to the understanding of the effect of a simultaneous exposition, and it may have interest in the evaluation of the damage degree to which humans are potentially exposed due to environmental pollution.

## MATERIAL AND METHODS

### *Animals and exposure:*

In this present experiment, twenty eight (28) male wistar rats were used, each weighing 250–300 g were purchased from the Pasteur Institute (Algiers). Animals were housed in polypropylene cages and maintained at ambient temperature of  $22 \pm 3^\circ\text{C}$  in natural photoperiod with relative humidity of 40-60%. The animals had free access to diet and water *ad libitum*. After 2 weeks of acclimatization period they were divided into four groups (seven animals for each exposure groups and control group). The first group (G1) served as control and received water as vehicle. In groups 2 and 3, rats were treated orally with Propiconazole at a dose of 60 mg/kg body weight, and Propineb with the dose 100 mg/Kg body weight propineb respectively. The last group (G4) animals were given the mixture of the two fungicides 30 mg/kg Propiconazole and 50 mg/kg Propineb. At 28 day of the treatment, the animals were sacrificed, blood and semen was collected. The organs (testes and epididymis) were removed and weighted.

### *Biological study of spermatozoa:*

To estimate the effect of fungicides used on the fertility of rats through the characteristics of sperm and semen quality, we proceeded to biology of spermatozoa by the method of the OMS 1993 [22]. After dissecting the semen collected from a small opening at the head of the epididymis to study the concentration, motility and spermatozoa vitality. Then 1  $\mu\text{l}$  of semen was preleved and diluted in 49  $\mu\text{L}$  of NaCl 0.9% then placed in an oven at a temperature of  $37^\circ\text{C}$ .

### *Histology study:*

The testes and epididymis samples were examined for histopathological changes. The samples were placed in 10% formole and dehydrated in 70–100% ethanol series. They were then placed in paraffin baths at  $58^\circ\text{C}$  for paraffin inclusion. Sections of 4–6 mm were prepared from paraffin blocks using a rotary microtome. These sections were then stained with Hematoxylin-Eosin (H-E) according to the criteria of the method of Martoja and Martoja [23], then photographed using a Leica photomicroscope.

### *Statistical analysis:*

Data are presented as mean  $\pm$  standard deviation (SD). The analysis of data was performed using *t*-Student test to compare the statistical significance of the differences between the treated and control groups with Minitab program (version 16).  $P < 0.05$  was considered significant.

### *Results:*

#### *Organs weight:*

Table 1 show the weight of the organs in the treated groups and control. It demonstrated a decrease in the weight of testis and epididymis of animals treated with propiconazole, propineb and mixture as compared to control.

**Table 1:** Changes in absolute and relative testes and epididymis weights of control and rats treated with propiconazole, Propineb and mixture after 28 days of treatment.

Parameters	Treatment groups			
	Control	Propiconazole	Propineb	Mixture
Absolute testes weight (g)	1,692 $\pm$ 0,060	1,541 $\pm$ 0,100*	1,587 $\pm$ 0,097	1,551 $\pm$ 0,092*
Relative testes weight (g/100g b.w.)	0,598 $\pm$ 0,045	0,540 $\pm$ 0,064	0,530 $\pm$ 0,071	0,526 $\pm$ 0,060*
Absolute epididymis weight (g)	0,631 $\pm$ 0,039	0,524 $\pm$ 0,074*	0,546 $\pm$ 0,052*	0,575 $\pm$ 0,041*
Relative epididymis weight (g/100g b.w.)	0,216 $\pm$ 0,018	0,182 $\pm$ 0,020*	0,181 $\pm$ 0,015**	0,194 $\pm$ 0,021

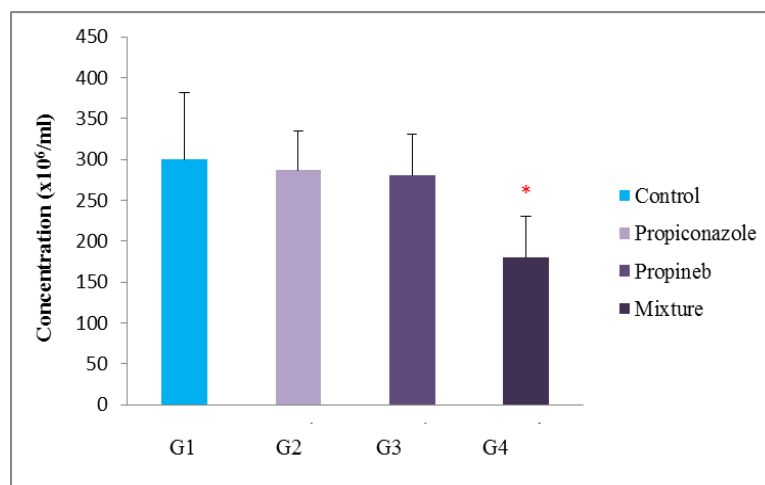
Values are given as mean  $\pm$  SD for group of 7 animals each.

\*  $P < 0.05$ , compared to controls.

\*\*  $P < 0.01$ , compared to controls.

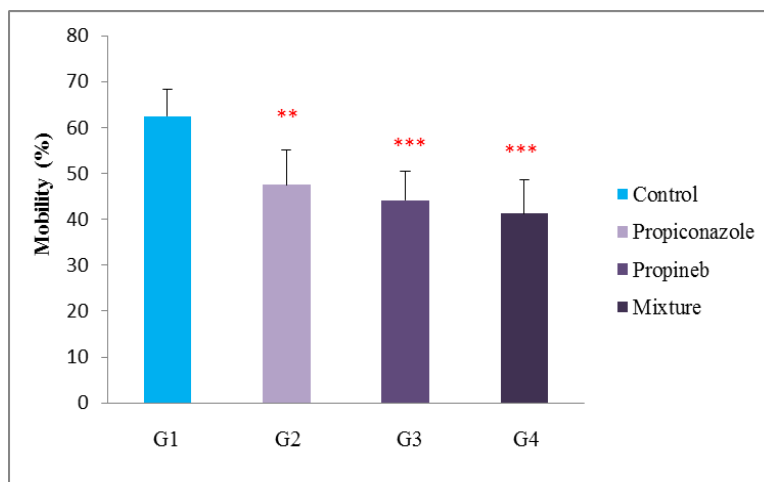
*Semen study:*

The results in Fig 1 show that there is a decrease but no significant change ( $P > 0.05$ ) in the concentration of spermatozoa in the treated animals with propiconazole and group propineb as compared to control group. However, there is a significant decrease ( $P \leq 0.05$ ) in the group treated with the mixture of Propineb and Propiconazole group as compared to the no treated animals.



**Fig. 1:** Epididymal sperm concentration of control and treated groups (x10<sup>6</sup>/ml). (M ± SD, n = 7)  $P < 0.05^*$ .

The results in Figure 2 show that there is a highly significant decrease ( $P \leq 0.01$ ) in the motility of the spermatozoa treated with propiconazole compared to controls. Similarly, a highly significant decrease was noted in the treated groups with propineb and the mixture as compared to those of control individuals.



**Fig 2:** Epididymal sperm motility of control and treated groups (%). (M ± SD, n = 7)  $P < 0.01^{**}$ ,  $P < 0.001^{***}$

The morphological changes characteristic of sperm exposed to hypo-osmotic stress are presented in (Table 2). We founded a significant reduction in the modification of flagellum of sperm category (A and B) between the treatment groups compared with the control group. However, the normal sperm was increased in the treatment groups compared to control group. The reduction in morphological changes of flagellums in the treatment groups indicates the adverse effect of Propiconazole, Propineb and mixture in sperm vitality by causing injury in the membrane of flagellum.

*Histology study:**Testes section:*

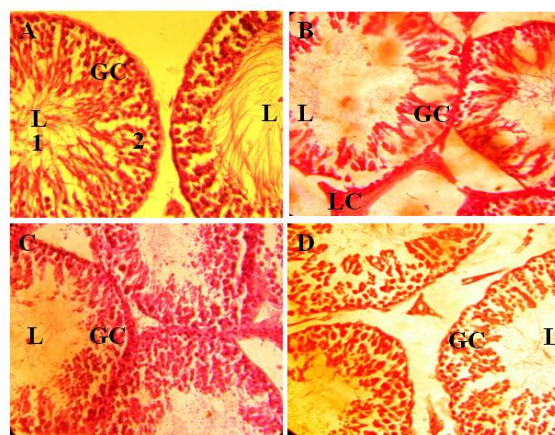
Observation from the histological sections (Figure 3, A to D) demonstrated apparently normal seminiferous tubules in controls with sperm cell series at different stages of development. The lumens were filled with a good population of mature sperm cells spermatozoa and a healthy interstitium was also demonstrable (Fig 3 A). The

testes of rats that received Propiconazole showed seminiferous tubules with poor intensity compared with the control group. The luminal diameter of the seminiferous tubules was also wider and the population of spermatozoa was markedly reduced. Generally, the spermatogenic cells appeared to have decreased in number compared to the control, and the characteristic shape of the seminiferous tubules was lost (Figure 3 B). Although tissue staining of the testes of rats administered with 100 mg/kg body weight Propineb was better than the low treated group with Mixture and Propiconazole as compared with the no treated the transverse section of testis in control animals, presence of wider luminal diameter and reduced interstitial spaces were noted, and the population of sperm cells was also reduced in the lumen.

**Table 2:** The morphological changes characteristic of sperm of control and experimental groups after 28 days of treatment.

Morphological changes	Treatment groups			
	Control	Propiconazole	Propineb	Mixture
A	25,56 ± 2,08	18,95 ± 4,70*	16,31 ± 5,27*	18,87 ± 4,61*
B	15,09 ± 3,15	17,01 ± 8,34	11,79 ± 2,03*	09,62 ± 3,27*
C	13,65 ± 4,4	15,70 ± 3,36	16,76 ± 5,49	13,24 ± 5,34
N	45,68 ± 3,17	47,75 ± 8,41	55,50 ± 10,7	58,27 ± 7,55*

Abbreviation: A, low modification in flagellum; B, significant modification in flagellum; C, modification important of flagellum and middle piece; N: normal (death) sperm. Values are mean ± SD (n = 7), P < 0.05\*, P < 0.01\*\*, P < 0.001\*\*\* compared to control.



**Fig. 3 A to D:** (A) Photomicrograph of the seminiferous tubules of the testis of rats in the control group showing apparently normal architecture: spermatogonia (white arrow), lumen (L) filled with mature sperm cells. (B) Photomicrograph of the seminiferous tubules of the testis of rats in the group 2 administered with 60 mg/kg Propiconazole showing reduced population of mature sperm cells in the lumen. (C) and (D) Transverse section of testis in the groups 3 and 4 treated with Propineb and the combination of the two fungicides 50/50% demonstrating wider luminal diameter, with reduced population of mature sperm cells in the lumen. L: Lumen of seminiferous tubules, GC: germinal cells, LC: Leydig cells. H&E stain (400x).

#### Epididymis section:

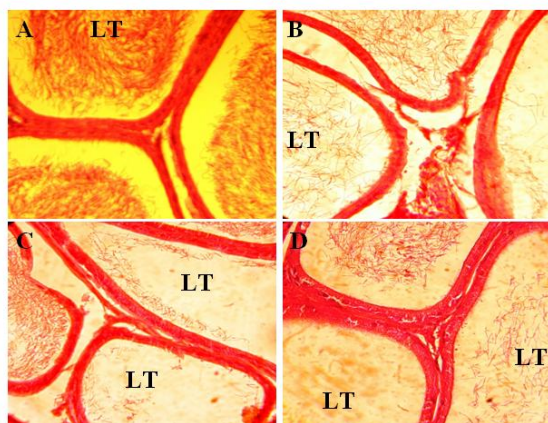
The examination transverse section of the epididymes from the control animals (Fig 4 A) of all groups showed normal structure and normal sperm density (+++) in the lumina of tubular sections. However, sperm density was found to be decreased in the experimental groups we observe moderate density of sperm in lumina of tubular section in the exposed rats to Propineb of 100 mg/kg after 28 days (Fig 4 C). The density sperm is low in the treated animals with the Propiconazole and many tubules are empty in the exposed animals with the mixture Propineb and Propiconazole.

From control rat showing sperm (+++) in the lumina completely filled. H&E, 400x; B. From rat exposed to Propiconazole of 60 mg/kg after 28days. Note that sperm density is moderate low (++) . H&E, 400x; C. From a rat exposed to Propineb treatments of 100 mg/kg body weight after 28 days. Note that many tubules are empty and others have fewer spermatozoa. H&E, 400x; D. From a rat exposed to mixture of fungicides Propiconazole/Propineb 50/50 % showing low (+) sperm density after 28 days. H&E, 400x. LT: Lumina Tubular.

#### Discussion:

Exposure to pesticides affects many body organs including reproductive system. Disorder of the reproductive system leads to infertility and therefore has been in the center of attention within the recent decades. Adverse effects of pesticides on the male reproductive system especially semen characteristics are an

important health problem in the all the world. Several international studies have been conducted on causes of endocrine disrupters, one of the most famous are pesticides, showing evidence of reduction in semen quality due to agricultural pesticides [24, 25].



**Fig. 4 A to D:** Photomicrographs of epididymes showing sperm density in the lumina of tubular sections; A.

The testes and epididymis weight of the treated animals decreased considerably in the three treated groups especially those treated with the Propiconazole and the mixture as compared to control. It has been reported that the gonads are target bodies of pesticides and which might be due to lowered bioavailability of androgens [26, 27]. The reduction in the weight of the testis could be due to inhibition of seminiferous tubule fluid formation and loss of germ cell by direct inhibition on spermatogenesis [28, 29]. Then, the data of this study demonstrated that Propiconazole, Propineb and the mixture could have an effect on the histological constitution of the cells of the testes. Many studies have been conducted to elucidate that the exposure to pesticides interferes with spermatogenesis by damaging the testes. The severity of affection depends on the stage of differentiation, can be reversible or irreversible, and may even temporarily lead to decreased fertility by modifying sperm count, structure motility, or viability of spermatozoa. These effects are transient because spermatogenesis is restored from stem cell populations after removal of the off ending chemical [30].

The used fungicides can act on the hypothalamic and hypophyseal hormones [31] by disturbing the secretion of GnRH which stimulates adenohypophysis to secrete LH (Luteinizing Hormone) and FSH (Follicle Stimulating Hormone) by modification of the receiving sites of LH on the level of the cells of Leydig [32] competition of the mixture and Propiconazole with LH affecting testosterone output [33, 34]. In addition, the treatment by maneb also can modify the secretion of FSH released by the cells of Sertoli which are necessary to the development of the seminiferous tubules through its role of nutrition [35].

The data of this study indicate that the exposure of the rats with Propiconazole, Propineb and Mixture of both caused a decrease in the concentration, motility and the vitality of the spermatozoa with anomalies in the histology study in the all treated groups as compared to the control animals. Similar effects have been observed that the testicular atrophy with damaged germinal epithelium and reduced sperm motility and viability were major findings in male adult rats exposed to maneb and zineb [36]. The decrease observed in the quantity and quality of the sperm can be explained by the effect of the used fungicide and also their mixture in spermatogenesis because it has already been reported that the sperms acquire motility and fertilizing ability only during their epididymal transit; Testosterone and Dihydrotestosterone are involved in the maturation of sperm within the epididymis as well as the transit of sperm through the duct [37, 38]. Any alteration in epididymal sperm count and motility provides a direct measure of fertility [39].

#### *Conclusion:*

In conclusion, we think that the repeated administration of fungicides used alone or in combination with the used doses in the same conditions by gavage may cause structural and functional disorders in the hormonal system.

#### **ACKNOWLEDGEMENTS**

We thank the members of the Animal Ecophysiology research group, especially Pr. Boulakoud Mohamed Salah for the technical and scientific support. The present study was part of the research project (Endocrine Disrupting Effects of Currently used Pesticides) aiming for assessment of the potential effects of currently used pesticides in Algeria from different pesticide groups.

## REFERENCES

- [1] Weiss, B., S. Amler, R.W. Amler, 2004. Pesticides. *Pediatrics*, 113 : 1030–1036.
- [2] Di Monte, D., 2003. The environment and Parkinson's disease: is the nigrostriatal system preferentially targeted by neurotoxins? *Lancet Neurol.* 2: 531-537.
- [3] Liu, B., H.M. Gao, J.S. Hong, 2003. Parkinson's disease and exposures to infectious agents and pesticides and the occurrence of brain injuries: role of neuroinflammation. *Environ. Health Persp.* 111: 1065–1073.
- [4] Bolognesi, C., G. Morasso, 2000. Genotoxicity of pesticides: potential risk for consumers. *Trends Food Sci. Tech.* 11: 182–187.
- [5] Lu, C., R.A. Fenske, N.J. Simox, D. Kalman, 2000. Pesticide exposure of children in agricultural community: evidence of household proximity to farmland and take home exposure pathways. *Environ. Res. Sect. A* 84, 290–302.
- [6] Quandt, S.A., T.A. Arcury, P. Roa, B.M. Snively, D.E. Camann, A.M. Doran, A.Y. Yau, J.A. Hoppin, D.S. Jackson, 2004. Agricultural and residential pesticides in wipe samples from farm worker family residences in North Carolina and Virginia. *Environ. Health Perspect.* 112(3): 382-387.
- [7] EFSA (European Food Safety Agency), 2008. Opinion of the Scientific Panel on Plant Protection products and their Residues to evaluate the suitability of existing methodologies and, if appropriate, the identification of new approaches to assess cumulative and synergistic risks from pesticides to human health with a view to set MRLs for those pesticides in the frame of Regulation (EC) 396/2005, 704: 1-84.
- [8] Sarkar, R., K.P. Mohanakumar, M. Chowdhury, 2000. Effects of an organophosphate pesticide, quinalphos, on the hypothalamo-pituitary-gonadal axis in adult male rats. *J. Reprod. Fertil.* 118: 29–38.
- [9] Lifeng, T., W. Shoulin, J. Junmin, S. Xuezhao, L. Yannan, W. Qianli, C. Longsheng, 2006. Effects of fenvalerate exposure on semen quality among occupational workers. *Contraception*, 73: 92–96.
- [10] Oliva, A., A. Spira, L. Multigner, 2001. Contribution of environmental factors to the risk of male infertility. *Hum. Reprod.* 16: 1768–1776.
- [11] Padungtod, C., D.A. Savitz, J.W. Overstreet, D.C. Christiani, L.M. Ryan, X. Xu, 2000. Occupational pesticide exposure and semen quality among Chinese workers. *J. Occup. Environ. Med.* 42: 982–992.
- [12] Swan, S.H., R.L. Kruse, F. Liu, D.B. Barr, E.Z. Drobnis, J.B. Redmon, C. Wang, C. Brazil, J.W. Overstreet, 2003. Semen quality in relation to biomarkers of pesticide exposure. *Environ. Health Perspect.* 111, 1478–1484.
- [13] IPCS (International Programme on Chemical Safety), 1993. Propineb. In: *Pesticide residues in food – 1993 toxicology evaluations*. WHO/PCS/94.4. World Health Organization, Geneva, 369-381.
- [14] IPCS (International Programme on Chemical Safety), 1999. Propineb. In: *Pesticide residues in food – 1999 Toxicology evaluations*.
- [15] Jones, R.D., 1999. Technical grade Antracol. A subchronic toxicity feeding study in beagle dog. Bayer Corp. Report No. BC8735 (EU Monograph in preparation).
- [16] Pauluhn, P., 1999. Pilot study of the subacute inhalation toxicity in rats (exposure 5-6 hours). LH30/Z 80VM 00705/1096 (c.n.: propineb). Bayer AG Report No. 28915 (EU Monograph in preparation).
- [17] Pauluhn, P., 2001. Subacute inhalation toxicity in rats – analysis of pulmonary toxicity (exposure 7-6 hours/day for 1 week). LH30/ Z 80VM 00705/1096 (c.n.: propineb). Bayer AG Report No. PH 30789 (EU Monograph in preparation).
- [18] Vanden Bossche, H., P. Marichal, J. Gorrens, M.C. Coene, G. Willemsens, D. Bellens, I. Roels, H. Moereels and P.A. Janssen, 1989. Biochemical approaches to selective antifungal activity. Focus on azole antifungals. *Mycoses* 32(Suppl. 1), 35-52.
- [19] Warmerdam, M.A., 2008. California Department of Pesticide Regulation Summary of Pesticide Use Report Data 2008 Indexed by Chemical, pp. 547, Sacramento, CA.
- [20] Van De Steene, J.C., W.E. Lambert, 2008. Validation of a solid-phase extraction and liquid chromatography–electrospray tandem mass spectrometric method for the determination of nine basic pharmaceuticals in waste water and surface water samples. *J. Chromatogr. A*, 1182: 153–160.
- [21] California, E.P.A., 2003. Summary of toxicology data. California Environmental Protection Agency, Department of Pesticide Regulation. In: <http://www.cdpr.ca.gov/docs/toxsums/toxsumlist.htm>
- [22] Organisation Mondiale de la Santé (O.M.S), 1993. Analyse du sperme humain et de l'interaction des spermatozoïdes avec le mucus cervical. Ed.INSERM, 55-56.
- [23] Martoja, R. and M. Martoja, 1967. Initiation aux techniques de l'histologie animale. Ed Masson and Cie, Paris, 345-346.
- [24] Tuc, V.P., V. Wangsuphachart, P. Tasanapradit, W. Fungladda, P. Van Trong, N.T. Nhung, 2007. Impacts of pesticide use on semen characteristics among rice farmers in Kienxuong District, Thaibinh Province, Vietnam. *Southeast Asian J. Trop. Med. Public Health*, 38: 569–575.
- [25] Hossain, F., O. Ali, U.J. D'Souza, D.K. Naing, 2010. Effects of pesticide use on semen quality among farmers in rural areas of Sabah, Malaysia. *J. Occup. Health*, 52: 353–360.

- [26] Kojima, S., Y. Sugimura, H. Hirukawa, M. Kiyozumi, H. Shimada, T. Funakoshi, 1992. Effect of dithiocarbamates on testicular toxicity in rats caused by exposure to cadmium. *Toxicology. Applied Pharmacology*, 116: 24-29.
- [27] Sujatha,, R., K.C. Chitra, C. Latchoumycandane and Mathur, 2001. Effect of lindane on testicular antioxidant system and steroidogenic enzymes in adult rats. *Asian J. Androl.*, 3: 135-138.
- [28] Joshi, S.C., N. Gulati and A. Gajraj, 2005. Evaluation of toxic impacts of mancozeb on testis in rats. *Asian J. Exp. Sci.*, 19(1): 73-83.
- [29] Ramesh, V. and B. Kumaran, 2013. Spermatotoxic Effect of Hexaconazole in Adult Rats. *Int. Arch. App. Sci. Technol.*, 4(2): 56-61.
- [30] Bretveld, R., M. Brouwers, I. Ebisch, N. Roeleveld, 2007. Influence of pesticides on male fertility. *Scand. J. Work Environ. Health*, 33: 13–28, Review.
- [31] Chapin, R.E., M.W. Haris and S.M. David, 1997. The effects of perinatal juvenile methoxychlor exposure on adult rat nervous, immune and reproductive system function; *Fundam. Appl. Toxicol.*, 40: 138-157.
- [32] Ksheerasagar, R.L. and B.B. Kaliwal, 2003. Temporal effects of mancozeb on testes, accessory reproductive organs and biochemical constituents in albino mice. *Environ. Toxicol. Pharmacol.*, 15: 9-17.
- [33] W.W.F (World Wildlife Fund) Canada, 1998. Resolving the DDT, World Wildlife Fund, USA, 52.
- [34] Schardein, J., 1993. Hormones and Hormone antagonists. In *chemically induced birth Defects*. 2nd ed. Chap.9: Dekker. New York, 271- 339.
- [35] C.P.P (Comité de la Prévention et de Précaution), 2001. Risques sanitaires liés à l'utilisation des produits phytosanitaires.
- [36] Lucier, G.W., I.P. Lee, R.L. Dixon, 1977. Effects of environmental agents on male reproduction in "The testis" vol-IV. Eds. By Johnson AD, Grames WR, 577 Academic Press, New York.
- [37] Bedford, J.M., 1979. Evolution of the sperm maturation and sperm storage functions of the epididymis in the spermatozoan (D.W. Fawcett and J.M. Bedford. Eds.). 7-21. Urban & Schwarzenberg, Baltimore.
- [38] Brooke, D.E., 1979. Biochemical environment of maturing spermatozoa in the spermatozoa (D.W. Fawcett and J.M. Bedford. Eds.), 23-24. Urban & Schwarzenberg, Baltimore.
- [39] Lemasters, G.K. and S.G. Selevan, 1993. Toxic exposures and reproduction: a view of epidemiology and surveillance. In: Scialli, A.R and Zinaman, M.J. (editors). *Reproductive Toxicology and Infertility*. McGraw Hill, 307-321.